



Case Report

Vulvar Donovanosis – An Unusual Cause of Genital Ulcer

Padmapriya Balakrishnan¹, Sharmila Vijayan²

¹Department of Pathology, Sri Lakshmi Narayana Institute of Medical Sciences, Puducherry, ²Department of Obstetrics and Gynecology, AIIMS, Mangalagiri, Andhra Pradesh, India.



*Corresponding author:

Dr. Sharmila Vijayan,
Professor and Head, Department
of Obstetrics and Gynecology,
AIIMS, Mangalagiri,
Andhra Pradesh, India.

sharu_jipmer@yahoo.co.in

Received: 30 June 2023
Accepted: 18 August 2024
EPub Ahead of Print: 04 October 2024
Published: 21 March 2025

DOI
10.25259/ICAJ_17_2023

Quick Response Code:



ABSTRACT

Genital ulcer is one of the common complaints which are encountered among adolescent and adult patients. Among the various causes, donovanosis is a rare entity due to the widespread use of antibiotics. Most of the genital ulcers are diagnosed clinically and treated empirically. Some need further evaluation when they do not respond to empirical treatment. Diagnosis is often delayed due to late presentation, lack of suspicion and use of inappropriate diagnostic investigations and treatment is challenging due to antibiotic resistance. We are presenting a case of vulvar donovanosis in a 40-year-old female patient diagnosed with cytopathology due to its rare incidence in this advanced antibiotic era.

Keywords: Donovanosis, Genital ulcer, Cytopathology

INTRODUCTION

Donovanosis, also known as granuloma inguinale or granuloma venereum, is a sexually transmitted infection caused by *Klebsiella granulomatis* (previously known as *Calymmatobacterium granulomatis*), a Gram-negative bacteria.^[1] It is a chronic progressive granulomatous ulcer affecting labia minora and fourchette in females and prepuce, glans penis and coronal sulcus in males.^[1,2] It was initially described by McLeod in 1882. We are reporting a case of vulvar donovanosis in a 40-year-old female diagnosed with cytopathology.

CASE REPORT

A 40-year-old parous perimenopausal lady presented to the gynaecology department with swelling over the vulva for 5 months duration, which was painless, non-itching, and not associated with any discharge. It started as a small papule and progressed to a present lesion in 5 months. There was no history of trauma, vaginal discharge, itching per vagina or bleeding per vagina. There was no history of human immunodeficiency virus (HIV), tuberculosis and extramarital sexual contact. On clinical examination, she had an ulcerated vulvar mass measuring 4 × 4 cm, which was non-tender, not indurated and was associated with active serosanguinous discharge. There was no inguinal lymphadenopathy. Per vaginal examination was normal. Considering differential diagnoses of infectious and neoplastic causes of vulvar ulcer, smears from serosanguinous discharge and Pap smear were taken. HIV serology was also done which was non-reactive. Pap smear was negative for intraepithelial lesion or malignancy. Cytopathological examination of discharge smear stained with Giemsa stain showed macrophages containing

This is an open-access article distributed under the terms of the Creative Commons Attribution-Non Commercial-Share Alike 4.0 License, which allows others to remix, transform, and build upon the work non-commercially, as long as the author is credited and the new creations are licensed under the identical terms.
©2024 Published by Scientific Scholar on behalf of Indian Cancer Awareness Journal

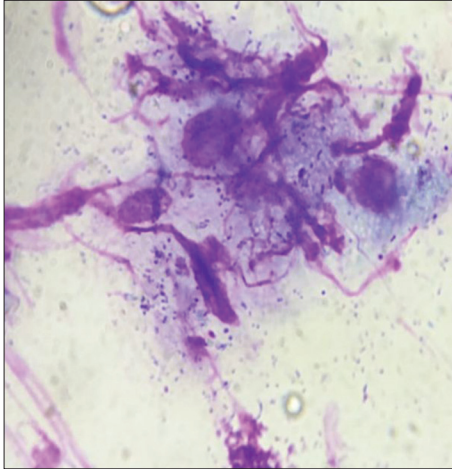


Figure 1: Cytology smear shows intracellular (macrophages) and extracellular Donovan bodies (Giemsa stain, ×100).

Donovan bodies, which are dark blue safety pin-shaped bipolar Gram-negative bacteria [Figure 1]. Diagnosis of donovanosis was made by the presence of Donovan bodies in the cytoplasm of macrophages. The diagnosis was confirmed by histopathological examination of ulcer edge biopsy, which also ruled out malignancy. The patient was treated with azithromycin 1 g orally weekly once for 4 weeks regimen, and she responded to treatment well.

DISCUSSION

The most common route of transmission of the organism causing donovanosis is sexual, followed by faecal contamination and autoinoculation; however, our patient denied sexual promiscuity.^[1] The disease usually starts as a small papule and then progresses to a nodule and ulcerated mass with a beefy red fleshy surface. Based on the appearance, there are four clinical variants-fleshy, sclerotic, hypertrophic and rapidly destructive lesion.^[3] Our case presented with a painless ulcerated vulvar mass similar to the cases described in the literature.^[1,4] Cases with extragenital lesions of donovanosis were also reported involving the oral cavity, vertebra, etc.^[5,6] Since *K. granulomatis* cannot be cultured, the gold standard method of diagnosing donovanosis is tissue biopsy stained with Giemsa stain showing Donovan bodies in macrophages, as demonstrated in our case, which also screens for the presence of malignancy.^[1,2,4] Donovan bodies are ovoid or bean-shaped bacteria and have a closed safety pin appearance on Giemsa staining due to the presence of blue chromatin inclusions at each pole.

Various treatment regimens are available with azithromycin, doxycycline, cotrimoxazole, ciprofloxacin, and erythromycin, and the regimen should be selected based on the antibiotic sensitivity of the organism for an earlier response.^[7,8] Early

diagnosis and appropriate treatment help in preventing complications such as pseudo elephantiasis of the vulva and malignant transformation, which necessitates vulvectomy.^[2,9] Cases of transformation of vulvar donovanosis ulcer into squamous cell carcinoma have been reported, emphasising the importance of earlier consultation and diagnosis of the cause of genital ulcer.^[1,2,4]

CONCLUSION

We diagnosed a case of vulval donovanosis in a 40-year-old patient who presented with an ulcerated vulvar mass by histopathologic examination. A clinician should consider donovanosis as one of the differential diagnoses while treating a patient with a genital ulcer to prevent a fatal malignant transformation of the lesion.

Author's contributions

Padmapriya Balakrishnan and Sharmila Vijayan were involved in the conception, literature search, analysis of data and drafting of the manuscript.

Ethical approval

The research/study complied with the Helsinki Declaration of 1964.

Declaration of patient consent

The authors certify that they have obtained all appropriate patient consent.

Financial support and sponsorship

Nil.

Conflicts of interest

There are no conflicts of interest.

Use of artificial intelligence (AI)-assisted technology for manuscript preparation

The authors confirm that there was no use of artificial intelligence (AI)-assisted technology for assisting in the writing or editing of the manuscript and no images were manipulated using AI.

REFERENCES

1. Agrawal M, Arora SK, Agarwal A. A Forgotten Disease Reminds Itself with a Rare Complication. *Indian J Dermatol* 2011;56:430-1.
2. Veeranna S, Raghu TY. A Clinical and Investigational Study of Donovanosis. *Indian J Dermatol Venereol Leprol* 2003;69:

- 159-62.
3. Rajam RV, Rangiah PN. Donovanosis; Granuloma Inguinale, Granuloma Venereum. Monogr Ser World Health Organ 1954;24:1-72.
 4. Sri KN, Chowdary AS, Reddy BS. Genital Donovanosis with Malignant Transformation: An Interesting Case Report. Indian J Sex Transm Dis AIDS 2014;35:135-7.
 5. Veeranna S, Raghu TY. Oral Donovanosis. Int J STD AIDS 2002;13:855-6.
 6. Paterson DL. Disseminated Donovanosis (Granuloma Inguinale) Causing Spinal Cord Compression: Case Report and Review of Donovanosis Involving Bone. Clin Infect Dis 1998;26:379-83.
 7. Marfatia YS, Menon DS, Jose S, Patel BK. Non Healing Genital Ulcer in AIDS: A Diagnostic Dilemma! Indian J Sex Transm Dis AIDS 2016;37:197-200.
 8. The Centers for Disease Control and Prevention; 2015. Available from: <https://www.cdc.gov/std/tg2015/donovanosis.htm> [Last accessed on 2023 Jun 23].
 9. Salomon B, Alemaena OK, Scrimgeour EM. Donovanosis (Granuloma Inguinale) with Vulval Pseudo-Elephantiasis. P N G Med J 1982;25:283-5.

How to cite this article: Balakrishnan P, Vijayan S. Vulvar Donovanosis – An Unusual Cause of Genital Ulcer. Indian Cancer Awareness J. 2024;3:59-61. doi: 10.25259/ICAJ_17_2023