

Case Report

Sertoli Cell Only Syndrome with Adenomatous Hyperplasia of Rete Testis – A Rare Combination of Two Benign Pathologies

Padmapriya Balakrishnan¹, Vijayan Sharmila², Thirunavukkarasu Arun Babu³

¹Department of Pathology, Sri Lakshmi Narayana Institute of Medical Sciences, Puducherry, ²Department of Obstetrics and Gynecology, All India Institute of Medical Sciences, ³Department of Pediatrics, All India Institute of Medical Sciences, Mangalagiri, Andhra Pradesh, India.



*Corresponding author:

Vijayan Sharmila,
Department of Obstetrics and
Gynecology, All India Institute
of Medical Sciences Mangalagiri,
Andhra Pradesh, India.

sharu_jipmer@yahoo.co.in

Received: 08 July 2023
Accepted: 26 July 2023
Epub Ahead of Print: 02 September 2023
Published: 25 July 2024

DOI
10.25259/ICAJ_18_2023

Quick Response Code:



ABSTRACT

Cryptorchidism is a common congenital anomaly and is associated with numerous pathological changes in gross morphology and histology of testis. Adenomatous hyperplasia of rete testis and sertoli cell only syndrome is rare benign histological changes in undescended testis. We report a case of undescended testis showing adenomatous hyperplasia of rete testis and sertoli cell only syndrome in a 13-year-old male in view of rare incidence, coexistence and also to insist on complete histopathological examination of undescended testis irrespective of presence of gross pathology.

Keywords: Adenomatous hyperplasia of rete testis, Sertoli cell only syndrome, Cryptorchidism, Inguinal hernia, Undescended testis

INTRODUCTION

Cryptorchidism is a common congenital anomaly and is notorious for various pathological changes of benign, premalignant and malignant nature. These changes occur due to abnormal location of testis, temperature changes, ageing and variable sensitivity for gonadal hormones. Adenomatous hyperplasia of rete testis (AHRT) and sertoli cell only syndrome (SCOS) are rare benign histological changes in undescended testis.^[1,2] Both are incidental finding without any gross pathology in majority of cases. AHRT is non-neoplastic epithelial proliferation of rete testis and mimics such as metastatic prostatic carcinoma and primary adenocarcinoma of rete testis. Hence, pathologist must differentiate between true malignant lesions of testis from this tumour like lesion.

CASE REPORT

We report a case of undescended testis showing combination of AHRT and SCOS in a 13-year-old male in view of rare incidence, coexistence and also to insist on complete histopathological examination of undescended testis irrespective of presence of gross pathology. A 13-year-old male child presented with acute abdominal pain for 1 day and a painless left inguinal swelling for 2 months. There was no history of trauma, fever or surgery in past. His general physical examination was normal and secondary sexual characteristics such as axillary hair and pubic hair

were developing. On abdominal examination, he had a non-tender, firm swelling in left inguinal region of 5×3 cm which was positive for cough impulse and irreducible. There was absence of left testis in scrotum. Right testis was present in scrotum. Vitals and other systemic examination were normal. With a clinical diagnosis of left irreducible incomplete inguinal hernia and left cryptorchidism, we proceeded for ultrasonogram. Ultrasound examination showed left inguinal hernia with omentum, part of small bowel and left undescended testis with preserved vascularity as content. Testicular volume was reduced with normal epididymis. Hernioplasty and left orchiectomy was performed under spinal anaesthesia. Grossly, testis was $4 \times 3 \times 3$ cm with attached spermatic cord of 4 cm long. Tunica vaginalis was intact. Cut section showed testicular parenchyma with negative string sign. There was no gross lesion in testis. Histopathological examination showed seminiferous tubules with basement membrane lined by sertoli cells only [Figure 1]. Some of the sertoli cells showed granular cell change [Figure 2]. There were few undifferentiated spermatogonia and focal prominence of Leydig cells. At periphery of testis, there were irregular tubular structures lined by columnar cells with scanty eosinophilic to clear cytoplasm, vesicular nucleus and dispersed fine granular chromatin which were infiltrating in between the nearby seminiferous tubules [Figures 3 and 4]. There were no nuclear atypia or mitotic figures in tubular structures. Epididymis and spermatic cord were normal. Based on clinical features and histopathological features, the diagnosis of undescended testis with AHRT and sertoli only cell syndrome was made. The patient was followed up for 3 months. There were no post-operative complaints.

SCOS is characterised by absence of germ cell in seminiferous tubules resulting from failure of migration of germ cells

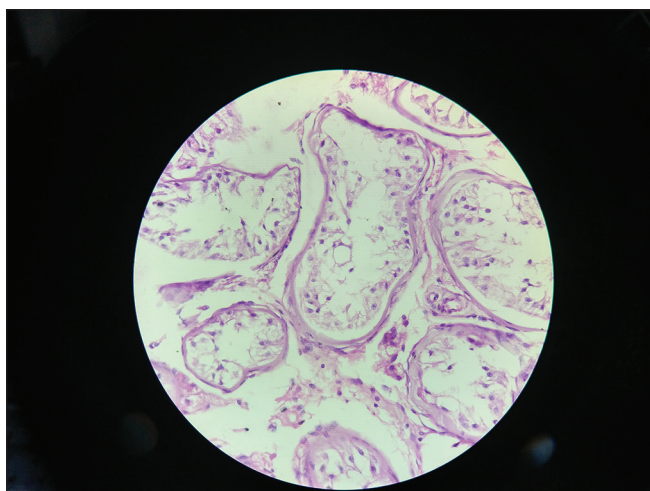


Figure 1: Photomicrograph showing seminiferous tubules with basement membrane lined by sertoli cells only. There was absence of germ cells ((Haematoxylin and eosin (H&E) stain, $\times 400$).

from primitive yolk sac to gonadal ridge. Germ cell to sertoli cell ratio in normal testis is 13:1, whereas, in present case with undescended testis, the ratio is 0:1. Granular change in cytoplasm of sertoli cells is also a histopathological change in undescended testis and is seen in present case. The various causes for SCOS are idiopathic, Klinefelter syndrome, 47XXY, chemical exposure and viral infections.^[3] SCOS occurs even in male with normal secondary sexual characters and descended testes. It causes male infertility and can be only by diagnosed by histopathology of testicular biopsy.

AHRT is diagnosed by presence of tubulopapillary or gland like configuration of cuboidal to columnar epithelial cells having vesicular nucleus with intervening collagenised stroma.

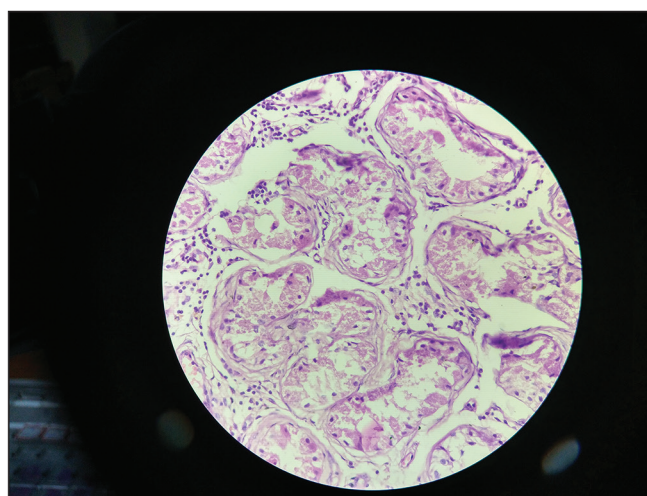


Figure 2: Photomicrograph showing sertoli cells with cytoplasmic granular change ((Haematoxylin and eosin (H&E) stain, $\times 400$).

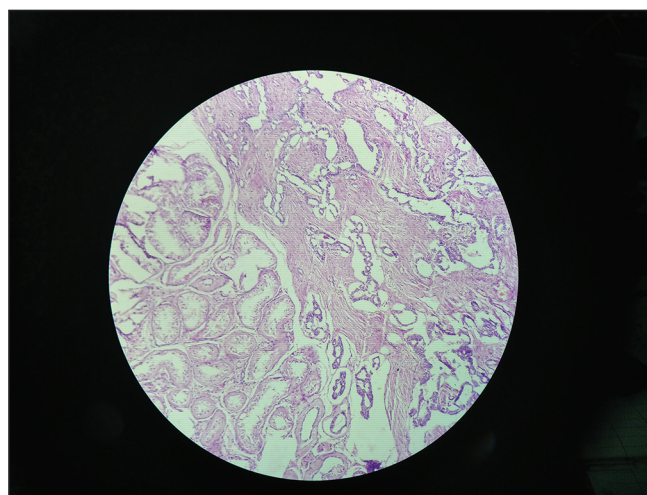


Figure 3: Photomicrograph showing adenomatous hyperplasia of rete testis composed of numerous irregular tubular structures with intervening collagenous stroma at periphery of testis ((Haematoxylin and eosin (H&E) stain, $\times 400$).

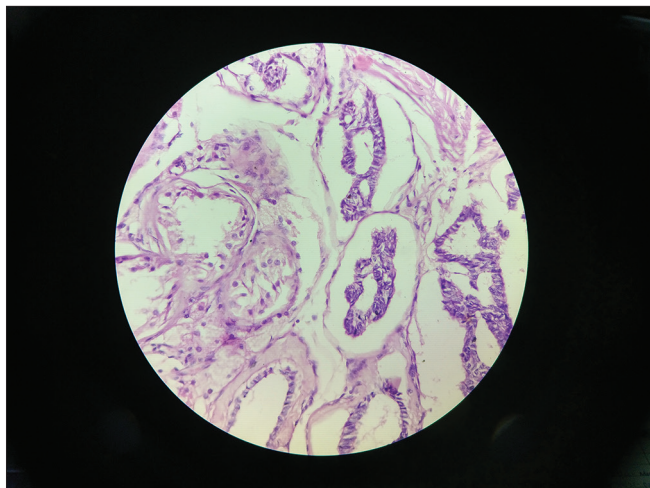


Figure 4: Photomicrograph showing adenomatous hyperplasia of rete testis with tubules lined by cuboidal to columnar epithelial cells having scant eosinophilic cytoplasm, vesicular nucleus and dispersed chromatin. Adjacent seminiferous tubules show sertoli cells only syndrome ((Haematoxylin and eosin (H&E) stain, ×400).

Sometimes, AHRT pseudo-infiltrates the seminiferous tubules and can be confused for infiltration by true malignant neoplasm. Pseudoinfiltration of AHRT was seen in present case. AHRT has to be differentiated from adenoma, primary and metastatic adenocarcinoma of rete testis, malignant mesothelioma of rete testis by clinical history, gross, histopathological findings and immunohistochemical analysis. Immunohistochemical panel such as epithelial membrane antigen, cytokeratin, prostate specific antigen, ki67 and calretinin is advised to diagnose AHRT and to rule differential diagnosis

A case of primary adenocarcinoma of rete testis with AHRT in a 36-year-old male was reported and suggested that AHRT may be a precancerous lesion of rete testis.^[4] In the present case, there was no evidence of adenocarcinoma.

The coexistence of AHRT and SCOS is rare and is seen in present case. A case of AHRT with SCOS in an undescended testis without any gross lesion in a 24-year-old adult phenotypic male was reported, whereas, in present case, the patient was male child.^[5] Thus, all testicular specimen warrants microscopic examination irrespective of gross pathology.

CONCLUSION

In the present case, immunohistochemical analysis, karyotyping, antimullerian hormone assay and testosterone assay were not done due to cost issues and lack of facility in our centre. Biopsy of other testicle was not performed to rule out AHRT and SCOS. Still, we believe in that this case report will benefit the readers about importance of histopathological examination of testis in cases of cryptorchidism and male infertility.

AHRT and SCOS are often incidental finding in a grossly normal testis. AHRT mimics malignancy and SCOS causes infertility. Undescended testis needs mandatory thorough gross and histopathological examination. Immunohistochemistry aids in accurate diagnosis in cases of dilemma.

Ethical approval

The Institutional Review Board approval is not required.

Declaration of patient consent

The authors certify that they have obtained all appropriate patient consent.

Financial support and sponsorship

Nil.

Conflicts of interest

There are no conflicts of interest.

Use of artificial intelligence (AI)-assisted technology for manuscript preparation

The author confirms that there was no use of artificial intelligence (AI)-assisted technology for assisting in the writing or editing of the manuscript, and no images were manipulated using AI.

REFERENCES

1. Catanzariti F, Servi L, Fabiani A, Filosa A, Mammanna G. Adenomatous Hyperplasia of the Rete Testis: A Rare Intrascrotal Lesion Managed with Limited Testicular Excision. *Arch Ital Urol Androl* 2016;88:243-4.
2. Ghanami GN, Sadighi GM, Abbasi M. Sertoli Cell-Only Syndrome: Etiology and Clinical Management. *J Assist Reprod Genet* 2021;38:559-72.
3. Hanmayyagari B, Guntaka M, Srinagesh. A Rare Case of Male Infertility: Sertoli Only Syndrome. *CHRISMED J Health Res* 2015;2:64-7.
4. Lin XY, Yu JH, Xu HT, Wang L, Fan CF, Liu Y, *et al.* A Case of Adenocarcinoma of the Rete Testis Accompanied by Focal Adenomatous Hyperplasia. *Diagn Pathol* 2013;8:105.
5. Ozgur T, Akin MM, Gokce H, Davarci M. Adenomatous Hyperplasia of the Rete Testis: Not a True Hyperplasia, Just Proliferation! *Contemp Oncol (Pozn)* 2013;17:466-7.

How to cite this article: Balakrishnan P, Sharmila V, Arun Babu T. Sertoli Cell Only Syndrome with Adenomatous Hyperplasia of Rete Testis – A Rare Combination of Two Benign Pathologies. *Indian Cancer Awareness J.* 2024;3:27-9. doi: 10.25259/ICAJ_18_2023