

## Case Report

# Carcinosarcoma of Uterus – A Case Report and Review of Literature

Vijayan Sharmila<sup>1</sup>, Padmapriya Balakrishnan<sup>2</sup>

<sup>1</sup>Department of Obstetrics and Gynecology, All India Institute of Medical Sciences, Mangalagiri, <sup>2</sup>Department of Pathology, Andhra Medical College, Vishakapatnam, Andhra Pradesh, India.



### \*Corresponding author:

Vijayan Sharmila,  
Department of Obstetrics  
and Gynecology, All India  
Institute of Medical Sciences,  
Mangalagiri, Andhra Pradesh,  
India.

sharu\_jipmer@yahoo.co.in

Received: 04 November 2022  
Accepted: 14 January 2023  
Epub Ahead of Print: 04 May 2023  
Published: 28 December 2023

DOI  
10.25259/ICAJ\_16\_2022

### Quick Response Code:



## ABSTRACT

Postmenopausal bleeding is a symptom that needs careful history taking, thorough clinical examination and further radiological investigations. Carcinosarcoma is an aggressive malignant neoplasm of the uterine corpus composed of malignant epithelial and mesenchymal components. We report a rare case of 75-year-old post-menopausal woman with post-menopausal bleeding diagnosed with carcinosarcoma of uterus. This case report emphasises the importance of typical clinical history, clinical findings and gross findings of carcinosarcoma for early clinical diagnosis.

**Keywords:** Carcinosarcoma, Malignant mixed Mullerian tumour, Post-menopausal bleed

## INTRODUCTION

Postmenopausal bleeding is a symptom that needs careful history taking, thorough clinical examination and further radiological investigations. Endometrial carcinomas are the most common malignancy causing post-menopausal bleeding. Sarcomas of uterus are rare neoplasms, yet easily be suspected with typical clinical presentation and gross appearance of tumour. According to the WHO classification (2014), carcinosarcoma of uterus accounts for <5% of neoplasms of uterine corpus.<sup>[1]</sup> Carcinosarcoma is an aggressive malignant neoplasm of uterine corpus composed of malignant epithelial and mesenchymal components.<sup>[2]</sup> The importance of this tumour lies in presentation at late stage which makes it inoperable and at high risk of metastasis resulting in poor prognosis. We report that a case of 75-year-old post-menopausal female with heavy vaginal bleeding was diagnosed to have carcinosarcoma of uterus by radiological findings and histopathology examination.

## CASE REPORT

A 75-year-old post-menopausal multiparous female came with complaints of bleeding per vaginum for 1 week associated with passage of blood clots. She also complained of low backache and lower abdomen pain for 1 week. Abdominal pain was dull aching in nature, mild in severity, localised to hypogastric region and non-radiating type. There was no history of fever, burning micturition, haematuria, mass per abdomen, mass per vaginum, abdominal distension and trauma. She was a known case of Type 2 diabetes mellitus and hypertension. There was no history of drug intake. On examination, pallor was present. Systemic examination was normal. On vaginal

This is an open-access article distributed under the terms of the Creative Commons Attribution-Non Commercial-Share Alike 4.0 License, which allows others to remix, transform, and build upon the work non-commercially, as long as the author is credited and the new creations are licensed under the identical terms.

©2023 Published by Scientific Scholar on behalf of Indian Cancer Awareness Journal

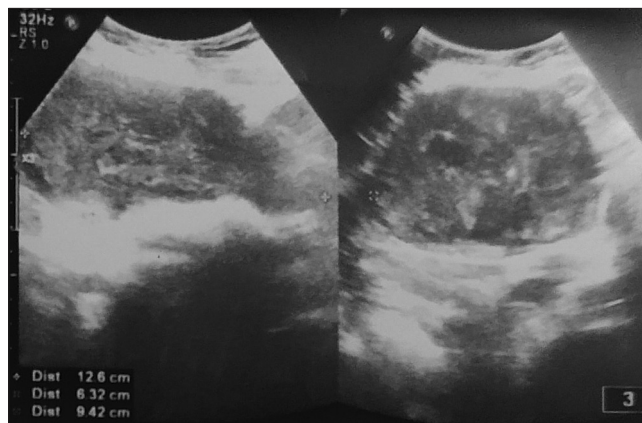
examination, vagina and cervix were healthy. Per speculum examination showed pulled up cervix pulled appearing as a rim around a mass. Endocervix was bulky, pulled up and bled on touch. The clinical diagnosis of endocervical mass probably polyp or carcinoma was considered. Haemoglobin was 4 g/dL and peripheral smear showed severe microcytic hypochromic anaemia. Chest X-ray was normal.

Ultrasonogram of abdomen and pelvis revealed an enlarged uterus (12.6 × 6.3 × 9.4 cm) with diffusely heterogeneous myometrium with few hyperechoic areas predominantly at the fundus [Figure 1]. Endometrium was thickened measuring 14 mm. There was no adnexal mass or no free fluid in pouch of Douglas.

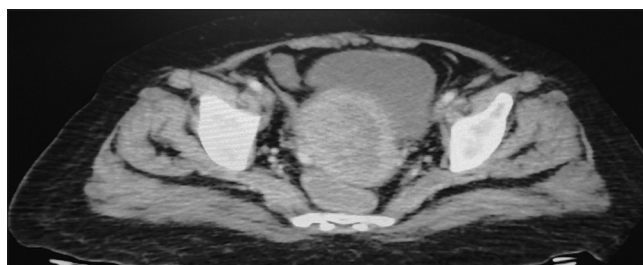
Computed tomography of abdomen and pelvis showed large non-enhancing mass lesion seen involving the endometrium and cervix measuring 75 × 45 mm suggestive of endometrial carcinoma. Myometrium was thinned out. The mass infiltrated endocervix, vagina and urinary bladder [Figure 2]. There was no abdominal or pelvic lymphadenopathy. There was no evidence of distant metastasis. Endometrial carcinoma (Tumor (T), nodes (N), and metastases (M) staging AJCC UICC 2017-T4 N0 M0) FIGO Stage IV A was suspected. Endometrial sampling was done and multiple soft haemorrhagic polypoidal tissue bits of size 3 × 2 cm were submitted for histopathological examination. Microscopic examination showed a biphasic polypoidal tumour composed of carcinomatous and sarcomatous components [Figure 3]. The carcinomatous component is composed of separate and discretely arranged sparse malignant endometrial glands of endometrioid type [Figure 4]. Glands were lined by pleomorphic columnar cells exhibiting atypical mitotic figures. The sarcomatous component was composed of compact bundles and fascicles of pleomorphic spindle cells exhibiting numerous atypical mitotic figures [Figure 5]. Carcinomatous and sarcomatous elements were not fusing with each other. There were wide areas of necrosis and haemorrhage in the tumour [Figure 6]. There was no heterologous differentiation in sarcoma component. The histopathological features were suggestive of carcinosarcoma of uterus (Malignant Mixed Mullerian Tumour of Uterus). As the tumour was FIGO (The international federation of gynecology and obstetrics) Stage IV, it was inoperable. She received blood transfusion followed by palliative external beam radiotherapy and neoadjuvant combination chemotherapy with ifosfamide and paclitaxel and is under follow-up.

## DISCUSSION

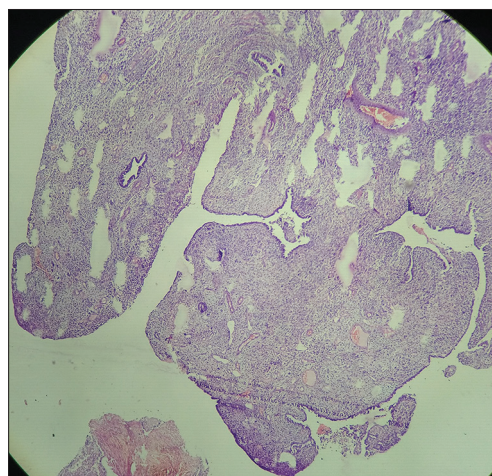
Carcinosarcoma of uterus is the one of the causes of post-menopausal vaginal bleeding. In our case, the history was



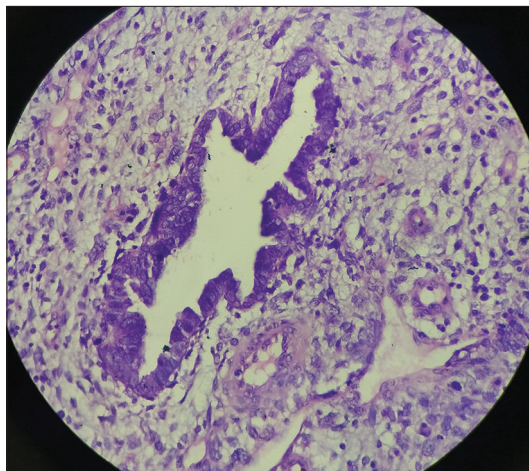
**Figure 1:** Ultrasonogram showed enlarged uterus of size 12.6 × 6.3 × 9.4 cm with diffusely heterogeneous myometrium with few hyperechoic areas predominantly at the fundus. Endometrium was thickened measuring 14 mm. There was no adnexal mass or no free fluid in pouch of Douglas.



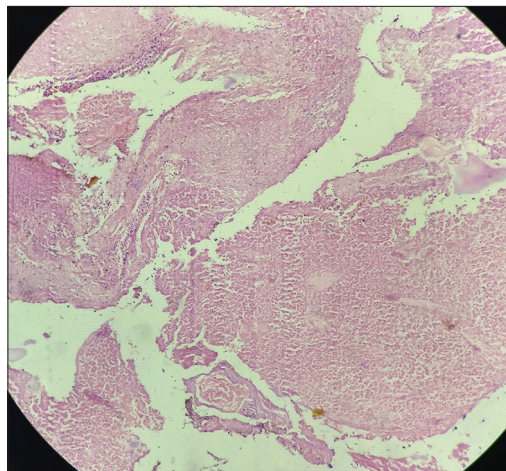
**Figure 2:** Computed tomography of abdomen and pelvis showed large non-enhancing mass lesion involving the endometrium measuring 75 × 45 mm suggestive of endometrial carcinoma. Myometrium was thinned out. The mass was invading the urinary bladder.



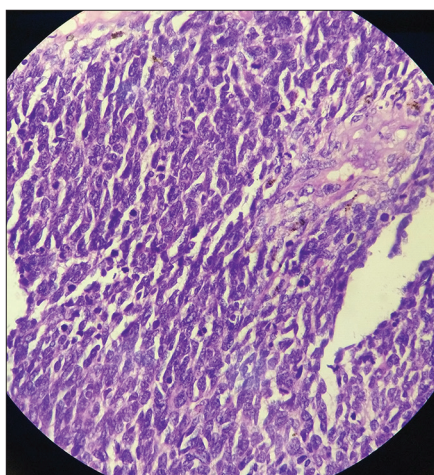
**Figure 3:** Microphotograph showing polypoidal nature of carcinosarcoma having carcinomatous and sarcomatous components (H&E stain, ×40).



**Figure 4:** Microphotograph of carcinoma component of tumour composed of separate and discrete malignant gland of endometrial type surrounded by sarcomatous component composed of fascicles of spindle cells with pleomorphic nuclei (H&E stain,  $\times 100$ ).



**Figure 6:** Microphotograph showing wide areas of necrosis in the tumour (H&E stain,  $\times 100$ ).



**Figure 5:** Microphotograph of sarcomatous component of tumour showing fascicles of spindle cells with pleomorphic nuclei exhibiting numerous atypical mitotic figures (H&E stain,  $\times 400$ ).

typical as described in the literature, that is, post-menopausal heavy bleeding in an elderly female with uterine mass protruding through the cervical os.<sup>[3]</sup> By ultrasonogram, the tumour was typically bulky, completely filling the endometrial cavity, extending up to cervical os, and invading the bladder at initial presentation.<sup>[4]</sup> Grossly, the sampled tumour tissue was soft, fleshy and haemorrhagic, typical of sarcoma.

In our case, the sarcomatous component was homologous and predominant. The tumour had sparse carcinomatous components. In a case of 67-year-old female with carcinosarcoma of uterus reported by Adachi *et al.*,<sup>[5]</sup>

the carcinomatous component was serous carcinoma in papillary pattern positive for p53 immunomarker. However, in our case, the carcinomatous component was of endometrioid adenocarcinoma type. As the tumour was not debulked completely, there may be possibility of presence of heterologous components such as rhabdomyoblastic, chondroid, or osseous elements in the existing part of tumour. Extensive sampling of tumours is essential as presence of rhabdomyoblastic elements carries poor prognosis.

For FIGO Stage IV disease, tumour debulking surgery along with post-operative external beam brachytherapy, combination chemotherapy with ifosfamide and paclitaxel was recommended.<sup>[6,7]</sup> The decision on surgical debulking must be taken based on general physical status of the patient.<sup>[8]</sup>

## CONCLUSION

Postmenopausal bleeding warrants detailed history taking, complete general physical examination and genital examination to reveal the underlying definite malignant aetiology. Carcinosarcoma of uterus is rare aggressive neoplasm requiring hysterectomy, bilateral salpingo-oophorectomy and adjuvant chemoradiotherapy for survival of patient. Typical clinical history and gross findings help for earlier clinical diagnosis which, in turn, navigates for needed investigations.

## Declaration of patient consent

The authors certify that they have obtained all appropriate patient consent.

## Financial support and sponsorship

Nil.

### Conflicts of interest

There are no conflicts of interest.

### REFERENCES

1. Carcangiu ML, Kurman RJ, Carcangiu ML, Herrington CS. Who Classification of Tumours of Female Reproductive Organs. Lyon: International Agency for Research on Cancer; 2014. Available from: <https://www.internet resource> [Last accessed on 2023 Jan 14].
2. Kurman RJ, Ellenson LH, Ronnett BM. Blaustein's Pathology of the Female Genital Tract. 7<sup>th</sup> ed. New York: Springer; 2011. p. 527.
3. Singh R. Review literature on uterine carcinosarcoma. J Can Res Ther 2014;10:461-8.
4. Kumar V, Abbas A, Aster J, Fausto N. Robbins Pathologic Basis of Disease. 9<sup>th</sup> ed. Philadelphia, PA: W.B. Saunders Company; 2014. p. 1018.
5. Adachi Y, Nonogaki H, Minamiguchi S, Li M, Ikehara S. Carcinosarcoma of the uterus: A case report. Mol Clin Oncol 2016;4:571-3.
6. Galaal K, Godfrey K, Naik R, Kucukmetin A, Bryant A. Adjuvant radiotherapy and/or chemotherapy after surgery for uterine carcinosarcoma. Cochrane Database Syst Rev 2011;2011:CD006812.
7. Vordermark D, Medenwald D, Izaguirre V, Sieker F, Marnitz S. The role of postoperative radiotherapy for carcinosarcoma of the uterus. Cancers (Basel) 2020;12:3573.
8. Denschlag D, Ulrich UA. Uterine Carcinosarcomas-diagnosis and management. Oncol Res Treat 2018;41:675-9.

**How to cite this article:** Sharmila V, Balakrishnan P. Carcinosarcoma of uterus – A case report and review of literature. Indian Cancer Awareness J. 2023;2:56-9. doi: 10.25259/ICAJ\_16\_2022